

# Clinical Experience with 4D Ortho Application

## Dynamic CT Post Processing of the Musculoskeletal System

Pedro Augusto Gondim Teixeira MD, PhD <sup>1)</sup>, Alain Blum MD, PhD <sup>1)</sup>



Pedro Augusto Gondim Teixeira MD



Alain Blum MD

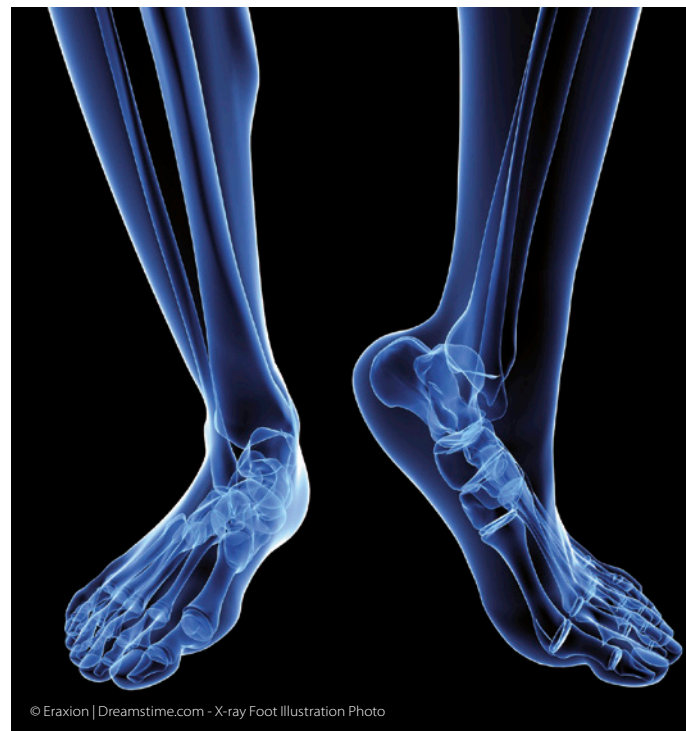Motion is frequently involved in the pathogenesis of musculoskeletal diseases. With static imaging methods, the diagnosis of dynamic pathology (e.g. friction and impingement syndromes) is based on secondary findings only<sup>1</sup>. This fact and the frequency of these conditions underscore the importance of dynamic imaging modalities in the evaluation of musculoskeletal diseases. Wide area-detector CT is suited to dynamic study of joints, allowing volumetric study of bone and intra-articular ligaments during physiologic motion or under stress maneuvers.

Dynamic CT is complementary to other dynamic methods, helping overcome some of their limitations, such as evaluation of bony and intra-articular structures with ultrasound or superimposition of structures on fluoroscopy<sup>2</sup>. Dynamic CT is most frequently used for the evaluation of the wrist, but can be used on various joints (shoulder, hip, elbow, knee, and ankle)<sup>3-5</sup>.

Up until now, the analysis of dynamic CT images was mostly subjective. Without specific tools quantitative analysis is time consuming and poorly reproducible, since measurement points must be selected manually on each acquisition volume (e.g. eight to ten per maneuver). Although subjective analysis of dynamic data is helpful in individual cases, developing general diagnostic criteria and scientific evaluation of the diagnostic performance with this method are hampered by the absence of quantitative data.

When performing musculoskeletal dynamic studies, a single motion or maneuver should be imaged per acquisition to avoid parasite motion (e.g. accessory motion distinct from target motion), which can complicate image interpretation. Parasite motion can be reduced by patient training and appropriate immobilization during acquisition, but complete suppression is difficult to achieve. When significant parasite motion is present, motion of one bone has to be evaluated relative to other moving structures, which may lead to diagnostic errors and makes the learning curve for the analysis of dynamic CT studies particularly long.

The 4D-Ortho application has two features that greatly improve analysis of dynamic joint studies by limiting the impact of subjectivity and parasite motion. Firstly, distance and angular measurements throughout



© Eraxion | Dreamstime.com - X-ray Foot Illustration Photo

the motion cycle can be obtained semi-automatically. Secondly, all motion can be displayed with respect to a given bone, which remains fixed or locked. Preliminary clinical testing of the 4D-Ortho tool is presented below.

### BASIC PRINCIPLES

Musculoskeletal dynamic CT is performed by acquiring multiple, low-dose volumes of the target zone during motion. The 4D-Ortho application is based on the

<sup>1)</sup> Service d'Imagerie Guilloz, CHU-Nancy, France

registration of each individual bone of the body part examined in all the acquired volumes. This is possible because, regardless of their respective position, bones are non-deformable structures. Once this process is completed, any point of any bone can be found automatically in all acquisition volumes.

4D-Ortho works as follows: All the volumes of a given dynamic acquisition are loaded. Multiplanar and a 3-D volume rendered images are displayed. Time controls allow the examiner to browse the images from all the volumes acquired. The examiner may then select a bone to be locked by placing a seed point anywhere within its medullary cavity (Fig. 1). Any bone can be selected - the target bone may vary depending on the evaluated pathology or the maneuver performed. After processing, all motion is displayed with respect to the locked bone, greatly reducing the influence of parasite motion.

Independently of the bone locking procedure, distances and angles can be measured with 4D-Ortho. The points selected for the measurement are plotted automatically to all volumes, increasing measurement reproducibility and greatly reducing post-processing time. To measure a distance, the volume that depicts the greatest distance between the points to be measured must be selected. Then, using multiplanar and/or volume rendered reformats, the points to be measured are selected. The selected point must be placed in the cortical bone near the bone surface, as opposed to the medullary cavity. Processing is launched, and once completed, the distances between the selected points throughout the motion cycle are displayed in a graphic (Fig. 2). The same procedure is applicable for angular measurements. By selecting two points within a bone and two points in another, two lines are created. The angle between these two lines can be measured automatically in all acquisition volumes (Fig. 3).

### CLINICAL EXPERIENCE

Since 2008, dynamic CT has been performed in our institution for the evaluation of musculoskeletal diseases. Wrist and ankle dynamic CT studies performed routinely were post-processed using the 4D-Ortho application. A total of ten studies were included in this analysis. All studies were performed with a 320 detector-row CT scanner (Aquilion ONE™, Toshiba Medical Systems, Otawara, Japan) using intermittent acquisition mode with a one second inter-volume interval. Acquisition lasted 8 to 12 seconds. Tube output parameters were adapted to patient anatomy<sup>2</sup>. In the wrist, radio-ulnar deviation was performed and in the ankle, prono-supination of the foot.

Bone locking was possible in all cases and improved visual analysis markedly, by reducing the influence of through-plane motion. In our opinion, the use of a static reference for motion analysis allows a better appreciation of the amplitude of the target motion and improves the analysis of each individual moving bone.

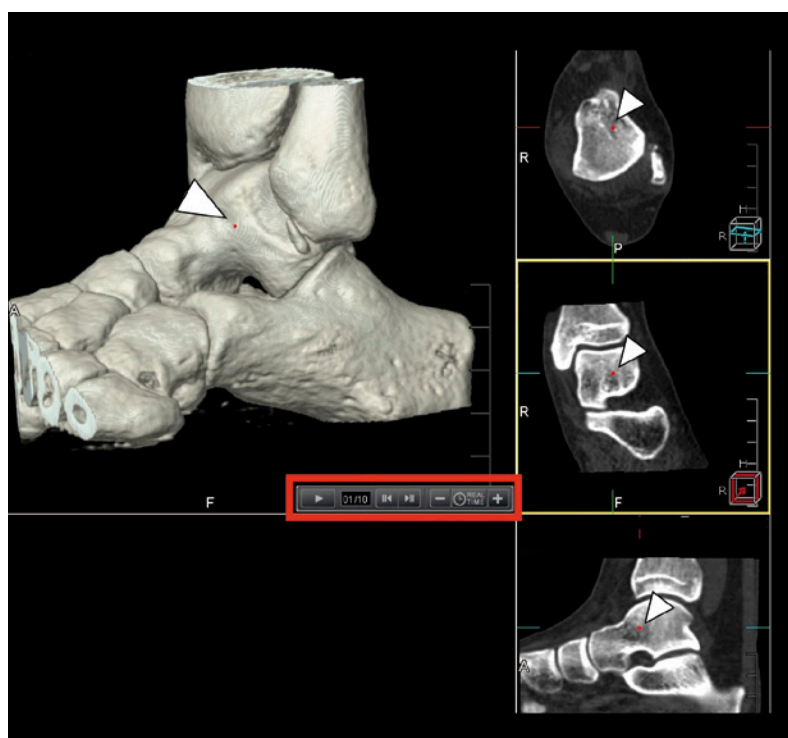

Figure 1: Bone locking procedure. A seed is placed in the medullary cavity of the bone to be locked (arrowheads). Position can be checked in both volume rendered and multiplanar images. Note the time controls (red square) allow browsing through all the volumes loaded.

Distance and angular measurements were feasible in all patients allowing quantitative analysis of clinical data. Measurement post processing may fail if the selected points are within areas of prominent motion artefacts, which should be avoided by optimal patient training and immobilization.

### DISCUSSION AND CONCLUSION

4D-Ortho was successfully used in the evaluation of clinical data, offering reproducible, semi-automatic measurements of distances and angles. Musculoskeletal dynamic CT is a relatively new technique and its clinical application is just beginning. Quantitative analysis is of great importance for the dissemination of this technique, since it facilitates the establishment of general diagnostic criteria that currently remain absent in literature. Clinical studies are currently being performed with the aid of 4D-ortho application in normal and pathologic patients, to assess normal and pathologic variation of distances and angles during different types of motion and in different joints.

Despite the importance of quantification in musculoskeletal dynamic CT, subjective analysis remains paramount for the interpretation of these studies. Visual understanding of motion paths and bone relations is important for diagnosis and may shed new light into the physiopathology of musculoskeletal diseases. In complex joints, such as the wrist, multiple carpal bones move with

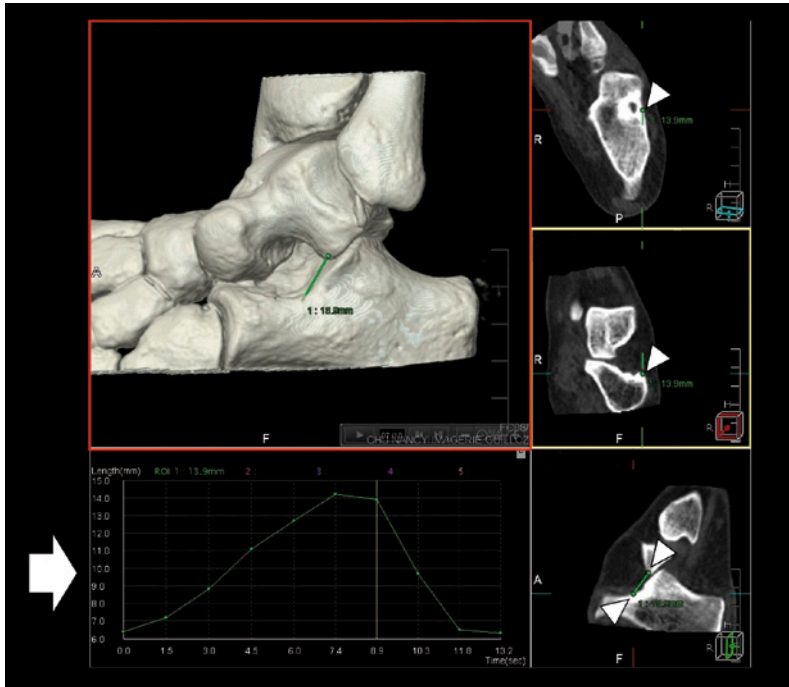


Figure 2: Two-point distance measurement with 4D-Ortho application during subtalar joint pronosupination. Two points are placed in the volume that shows the largest distance between the points to be evaluated (red square). The exact location of the selected points is displayed on the multiplanar images (arrowheads). Note that the points are located in the cortical bone and not in the medullary cavity. After post processing, the graphic on the lower right shows the distance variation (arrow).

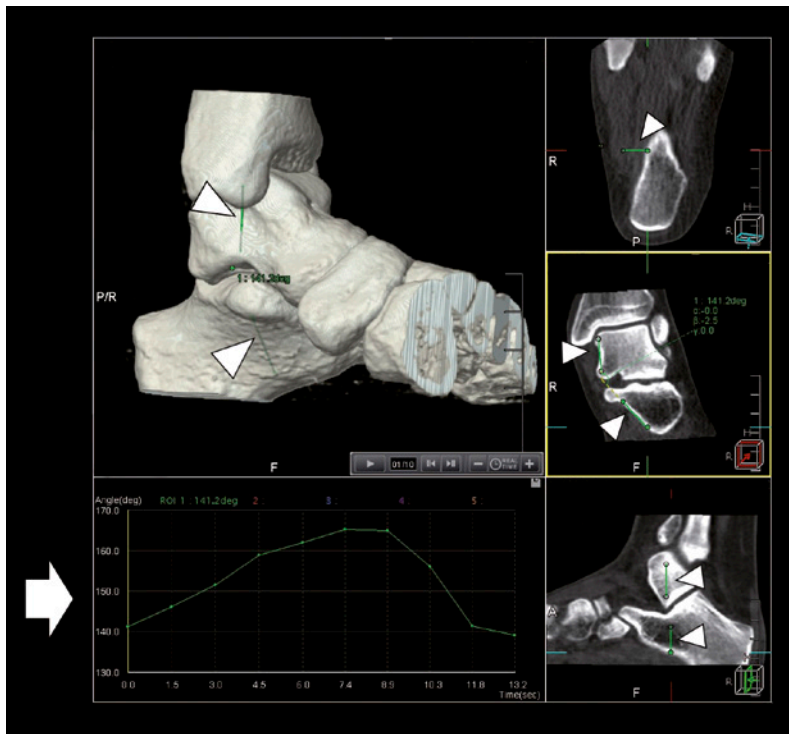


Figure 3: Four-point angular measurement with 4D-Ortho application during subtalar joint pronosupination. Two points are placed in two different bones, in this case the talus and the calcaneus. The selected points are shown both in the volume rendered and multiplanar images. Two lines intersecting the selected points are seen (arrowheads). After post processing, the graphic on the lower right shows the variation in the angle between these two lines (arrow).

respect to each other, adding to the complexity of the analysis. Bone locking improves visual analysis of dynamic data, making it easier to appreciate fine motion and bone displacement.

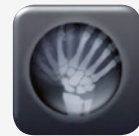In conclusion, 4D-Ortho represents a major development in the post processing of musculoskeletal dynamic CT. This application has the potential to improve diagnostic performance and reproducibility of musculoskeletal dynamic CT, playing an important role in the clinical application of this technique.

### CT FUNCTIONAL SUITE - CAPTURE HUMAN MOTION

The wide 16 cm z-axis coverage provided by the Aquilion ONE™ and Aquilion ONE /VISION Edition makes these systems ideal for capturing motion and flow with true dynamic volume acquisition. Toshiba offers a wide range of advanced applications to facilitate both qualitative and quantitative functional analysis for more accurate diagnosis and treatment planning.

### 4D ORTHOPEDIC ANALYSIS

Patients who suffer from pain during movement in a variety of everyday activities often have no obvious structural abnormalities. Dynamic volume scanning is able to capture the often complex mechanical abnormalities responsible for the patient's symptoms. The 4D Orthopedic Analysis application enables superior visualization and quantification of joint motion to more accurately identify any abnormalities.



#### Bibliography

1. Guillin R, Marchand AJ, Roux A, Niederberger E, Duvauferrier R. Imaging of snapping phenomena. Br J Radiol. 2012 Oct;85(1018):1343–53.
2. Gondim Teixeira PA, Gervaise A, Louis M, Lecocq S, Raymond A, Aptel S. Musculoskeletal Wide detector CT: Principles, Techniques and Applications in Clinical Practice and Research. European Journal of Radiology. 2015 (in press);
3. Wassilew GI, Janz V, Heller MO, Tohtz S, Rogalla P, Hein P, et al. Real time visualization of femoroacetabular impingement and subluxation using 320-slice computed tomography. J Orthop Res. 2013 Feb;31(2):275–81.
4. Totterman S, Tamez-Pena J, Kwok E, Strang J, Smith J, Rubens D, et al. 3D visual presentation of shoulder joint motion. Stud Health Technol Inform. 1998;50:27–33.
5. Edirisinghe Y, Troupis JM, Patel M, Smith J, Crossett M. Dynamic motion analysis of dart throwers motion visualized through computerized tomography and calculation of the axis of rotation. J Hand Surg Eur Vol. 2014 May;39(4):364–72.